International Journal of BioMedicine 3(1) (2013) 23-26

INTERNATIONAL JOURNAL OF BIOMEDICINE

CLINICAL RESEARCH

Comparing the Morphological Changes in Burn Wound Tissues and the Procalcitonin Concentration

Ludmila I. Budkevich, PhD, ScD[2], Andershan U. Lecmanov PhD, ScD[1,2], Elena G. Kolokolchikova, PhD, ScD[3], Vera V. Soshkina, PhD[1]

[1]*Moscow Scientific Research Institute of Pediatrics & Pediatric Surgery, Moscow, Russian Federation*
[2]*Moscow Children's Hospital #9, Moscow, Russian Federation*
[3]*N. V. Sclifosovsky Research Institute of Emergency Care, Moscow, Russian Federation*

Abstract

The problem of early diagnostics of bacterial complications is particularly true for children with extensive burn trauma (BT). Procalcitonin concentration levels considerably facilitate the diagnosis of sepsis. In all, 50 children with severe burns were included in our research. We conducted histological tests of the burn wound tissues from 13 patients. On comparison of the results of the PCT-tests with the results of the morphological investigation, we observed that the depth of the penetration of the microorganisms in the damaged tissues quite precisely corresponded to changes in the procalcitonin concentration.

Key words: *burn trauma, PCT-tests, procalcitonin*

Introduction

Over the last two decades, the development of burn treatment has led to a major decrease in mortality. Major advances have been made in the treatment of inhalation injury. But until the present, infection remains one of the basic problem of extensive BT [1-5].

Despite the degree of success achieved in burn treatment, the mortality level remains constant during the victim's long spell with severe BT. This problem is especially true for children with severe burns. Early diagnosis of sepsis enables us to define the optimum benefits of antibacterial therapy in time, which definitely influences the disease outcome.

***Corresponding author**: Vera V. Soshkina, PhD, Moscow Scientific Research Institute of Pediatrics & Pediatric Surgery. Moscow, Russian Federation.*

E-mail: vsoshkina78@yandex.ru

Extensive BT results in the development of toxemia, if symptoms of systemic inflammatory response syndrome (SIRS) are revealed within the first few hours of the disease. The greatest problem is the early differential diagnoses between the onset of SIRS and the initial symptoms of the septic process. In this connection, the early diagnoses of long-term sepsis can be determined by a complex of clinical criteria, microbiological research and laboratory parameters which are not always done quickly, objectively and unequivocally, to estimate the degree and activity of infectious onset, to be able to predict its current and outcome [6-11]. Thus, employing traditional criteria is not completely sufficient. The search for biochemical markers which allows the diagnostic development of bacterial complications as early as possible must be the foremost step.

In this connection, the long search for an authentic highly specific marker for sepsis was conducted. This marker must precisely reflect the degree of the process and productivity of the treatment. In the present stage, the procalcitonin (PCT) test fulfils all the listed requirements. Since its introduction in

clinical practice in the Western European countries from 2000, a real breakthrough was made in the problem of diagnostics and monitoring of heavy bacterial infections. PCT-test is approved by FDA (USA) and recommended to wide clinical application since 2005 [12-17].

On onset of bacterial infection, a rise in the blood PCT concentration was observed. The PCT level rises against a background of systemic inflammation caused by bacterial infections, although the PCT concentration remains low in the case of inflammation caused by other factors. This was confirmed by later research studies. This fact promoted that the concept that PCT could be used as a reliable marker of a bacterial infection [18-21]. The common argument raised against this was the possible discrepancy of the PCT- test information, in the case of extensive burn trauma.

The purpose of this study was to define the diagnostic value of the PCT test for the early diagnoses of sepsis in children with severe burn injuries and to conduct morphological research studies of burn wound tissues in view of the measurement of PCT concentration levels.

Material and Methods

In this research, we included 50 children between 6 months and 14 years of age (middle age 3.8±2.6 years), with general burn wounds areas from 20% to 90% of total surface of body area (TBSA), with full-thickness wounds including 5% to 90% TBSA. P**atients** were treated in the clinic of Moscow Scientific Research Institute of Pediatrics & Pediatric Surgery between January 2004 and June 2007. All the children were admitted into the specialized unit within the first 24 hours post BT.

Besides running the standard clinical and laboratory tests, intensive care monitoring, clinical and biochemical blood analyses, definition of C-reactive protein (CRP) level, measurement of the blood acid-basic and electrolyte balance, microbiological research of burn wounds with definition of sensitivity of flora to the antibiotics, we measured the semi-quantitative PCT levels ("PCT-Q", BRAHMS, Germany) and quantitative PCT blood concentrations (BRAMS PCT LIA, Germany) on the first and seventh day after BT. Morphological studies of the changes in burn tissues and definition of the depth of microorganism penetration into the wounds was carried out in parallel. A study of the bacterial invasion and depth of bacterial penetration into the wounds was done in 13 victims. 30 examples of burned tissues were investigated. The research is based on the standard and accepted histological methods of fixing, painting and microscopic study of tissues.

All the data was processed employing the variation statistical methods using the software Statistica for Windows 6.0.

Results

From investigations conducted on the 50 patients we arrived at the following conclusions. The clinical evidence of the disease in 18 (36%) children corresponded to SIRS with a PCT level of less than 0.5 ng/mL. Totally nine patients (23%) ran the risk of developing infectious complications identified by a PCT concentration of more than 0.5 ng/mL, but less than 2 ng/mL. Sepsis was diagnosed in 15 (30%) victims (PCT more than 2 ng/mL). PCT values exceeding 10 ng/mL was observed in 8 (16%) burn patients, which implied severe sepsis and served as a bad prognostic sign in disease outcome. The diagnosis of "sepsis" was verified 5.8±4.2 days post trauma.

Morphological research of the burn wound tissues was done in 13 victims and 30 samples were investigated. The area of the burn wounds in these children ranged from 20% up to 50% TBSA (38.6±3% TBSA); their age has been about 2.1±1.3 years. Sepsis was registered in five (38.5%) patients, where the PCT concentration exceeded 2 ng/mL, and for two (15.4%) victims within this group bacteremia was confirmed. In all, four (30.7%) burn patients were suspected to have sepsis, and they revealed unitary increase of the PCT level to more than 0.5 ng/mL on the 3rd - 4th day after BT. SIRS was diagnosed in four case (30.7%); PCT concentration was less 0.5 ng/mL.

We did not identify any case of PCT concentration increasing to more than 0.5 ng/mL within the first 24 hours post BT. We thus concluded that extensive burn trauma without inhalation injury by itself is not the reason for the increase in the PCT level.

During research, tests were conducted on the burn wound tissues of four patients with SIRS (PCT: 0.41±0.05 ng/mL); 10 samples were tested, and the following changes were observed: neutrophil infiltration of the epidermis and the presence of microbes and microbial detritus on the surface. The cellular reaction expressed congestion of leukocytes and macrophages around the vessels. Destruction of some vessels, and thrombosis with erythrocyte stasis was observed. Necrosis and papillary dermal infiltration, with destruction of a mesh layer were investigated. Microbial detritus and separate bacteria in the destroyed sites of the layer were observed. The given changes are illustrated in Fig. 1-2.

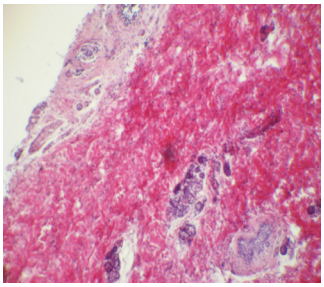

Figure 1.
In the site of the papillary derma studied, a cellular reaction is visible around the vessels, expressed as a congestion of the leukocytes and macrophages. Vessel destruction, thrombosis, and erythrocyte stasis are observed, which are destructive changes of the reticulate derma. Hematoxylin and Eosin x 100.

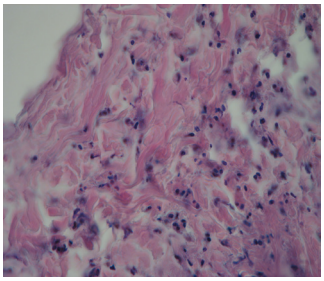

Figure 2.
Reticulate derma with the expressed destructive changes. Infiltration by leukocytes; separate bacterial cells in the thickness of the derma. Hematoxylin and Eosin x 630.

Totally, 10 samples of the wound tissues from four victims with the threat of development of sepsis (PCT – 1.24±0.3 ng/mL) were investigated. The following picture was observed: formation of a necrotic layer on the tissue surface with its penetration into the depth of the derma. The following changes were observed: hypostasis, destruction, necrosis and infiltration by leukocytes into the deep dermal layer. Bacterial penetration into the necrotic layer and through the full thickness of the derma, and vessel destruction with infiltration by leukocytes were evident. Massive neutrophil infiltration into the full thickness of the derma and

subcutaneous fat and fusion by leukocytes were investigated. The given changes are illustrated in Fig. 3-4.

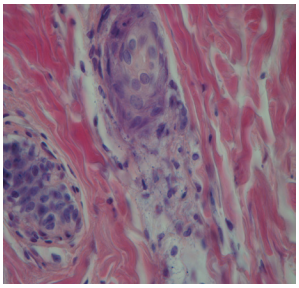

Figure 3.
Microbes in a grease iron of a hair follicle with the expressed destructive changes. Hematoxylin and Eosin x 630.

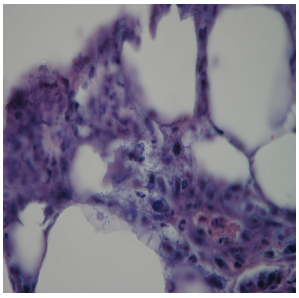

Figure 4.
Invasion of the microorganisms, necrotic changes and infiltration of the leukocytes and macrophages in subcutaneous fat seen. Hematoxylin and Eosin x 630.

We tested 12 tissue samples from three patients with confirmed bacterial complications identified by PCT concentration more 2 ng/mL (3.8±1.2 ng/mL). The following changes were seen occurring within the samples: necrotic changes and infiltration by leukocytes into the full thickness of the derma with massive bacterial invasion. Bacterial penetration into the blood vessels and subcutaneous fat was observed, and their ultimate destruction. Microorganisms and detritus were seen in the gleam of the blood vessels. Hair follicles showed necrosis. Plenty of destroyed neutrophils and microbes were visible on the subcutaneous fat surfaces. The given changes are illustrated in Fig. 5-6.

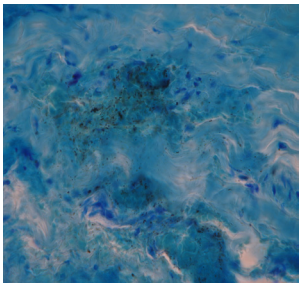

Figure 5.
Colonies of bacteria (black color) in the thickness of the derma. Toluidine blue x 630.

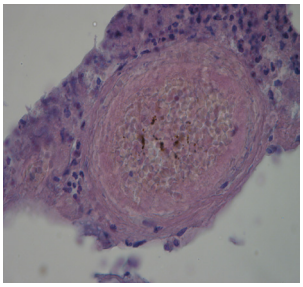

Figure 6.
Thrombosis of the large vessel. There are microbes (dark points) and thrombosis in a gleam of a vessel. Hematoxylin and Eosin x 630.

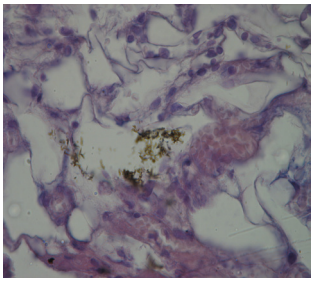

Figure 7.
Expansion of the gleams of vessels and stasis of erythrocytes. in the subcutaneous fat. Colonies of microorganisms in observed at the center (a congestion of black color). Hematoxylin and Eosin x 630.

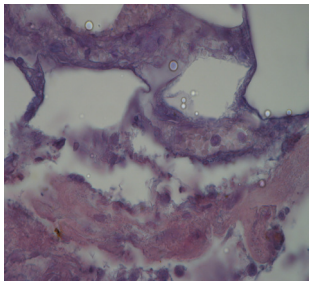

Figure 8.
Necrotic changes in the deep layers of a skin. Microbes and microbic detritis in the tissues. Destruction of cells and vessels. Hematoxylin and Eosin x 630.

Severe sepsis (PCT – 13.4±2.1 ng/mL) was confirmed in two burn patients (8 samples of tissues were investigated), characterized by the following morphological evidences: microbial invasion of the blood vessel walls and their destruction. Bacteria, necrotic substances and erythrocyte stasis were in the gleams of vessels. Expansion of the gleams of the vessels was observed in all the cases. Necrosis of skin appendages was seen. Penetration of the microorganisms into the depth of the derma and subcutaneous fat was noted. The muscular layer was fused by leukocytes. The lack of inflammatory cells was a sign of the absence the reaction of an organism on bacterial invasion. The given changes are illustrated in Fig. 7-8.

Discussion

According to some authors, severe BT causes the increase in the blood PCT concentration, and limits the use of the PCT-test for diagnosis of the beginning of sepsis in burns patients [4,16]. The results of our research show that extensive burns without inhalation injury by itself cannot be the reason for the increased PCT levels. Hence, the increased PCT concentration in severs burn injuries testifies to the involvement of bacterial complications which provides the basis for the extensive usage of quantitative and semi-quantitative measurements of PCT in clinical practice for the early diagnosis of sepsis development.

The results of the morphological research completely concurred with our estimation of the severity of the infectious process. We observed the presence of the microorganisms in the superficial wound layers, without their penetration into the skin appendages in cases of no bacterial complications. A condition regarded by us as threat of a sepsis – PCT > 0.5 ng/mL – revealed a morphological pattern, characterized by the penetration of microorganisms into the entire thickness of the derma. In the case of a current of septic process – PCT ≥ 2 ng/mL - a marked bacterial invasion of the entire depth of the derma is observed. In one stage a massive infiltration by the leukocytes throughout the whole thickness of the derma was recorded. Heavy sepsis - PCT ≥ 10 ng/mL - characterized by the presence of bacteria in a gleam of vessels, showed penetration of the microorganisms into the whole thickness of the derma and subcutaneous fat. Marked muscle destruction by the leukocytes is also seen. The lack of neutrophils and macrophages in the tissue testifies to the absence of any reaction by the organisms to the infectious process.

We thus revealed a connection between the PCT concentration and the condition of burn wounds in our morphological research. Precisely, the depth of penetration of the microorganisms into a wound corresponds exactly to changes in the PCT level. It also confirms the ability to base a diagnostic estimation of a patient's condition on the results of the PCT-test.

Conclusion

Extensive burn trauma without inhalation injury is not the reason for the increase in the PCT concentration. The rise in the PCT level is merely a sign of bacterial complications.

The depth of the bacterial penetration into the burn wounds precisely corresponds to a change in the PCT level, thus confirming the diagnostic value of the PCT test for identification of the infectious processes.

References

1. Barret JP, Herndon DN. Effects of burn wound excision on bacterial colonization and invasion. Plast Reconstr Surg 2003; 111(2):744-50; discussion 751-752.
2. Becker KL, O'Neil W J, Snieder RHJr,Nylen ES, Moore CF, Jeng J, et al. Hypercalcitonemia in inhalation burn injury: a response of pulmonary neuroendocrine cell? Anat Rec 1993; 236(1): 136-138, 172-173; discussion 138-43.
3. Fitzwater J, Purdue GF, Hunt JL, OKefe GE. The risk factors and time course of sepsis and organ dysfunction after burn trauma. J Trauma 2003; 54 (5):959-66.
4. Ward CG, Splanding PB, Marcial E, Bullen JJ. The bactericidal power of blood and plasma of patients with burns. J Burn Care & Rehabil 1991; 12(2):120-126.
5. Winkler M, Erbs G, Muller FE, Konig W. Epidemiologic studies of the microbial colonization of severely burned patients. Zentralbl Bakteriol Mikrobiol Hyg 1987; 184 (3-4):304-20.
6. Ayala A, Chaudry IH. Immune dysfunction in murine polymicrobial sepsis:mediators, macrophages, lympocytes and apoptosis. Shock 1996; 6 Suppl 1:27-38.
7. Bayona OEN. Bacterial infection, sepsis and procalcitonin (in Spanish). Medica Santas 2001; 4(5): 19-21.
8. Bone R'C, Balk RA, Cerra FB, Dellinger RP, Fein AM, Knaus WA, et al.. Definitions for sepsis and organ failure and guidelines for the use innovative therapies in sepsis. The ACCP/SCCM Consensus Conference committee. American College o Chest Physician/Society of Critical Care Medicine. Chest 1992; 101(6):1644-1655.
9. Brill RJ, Goldstein B. Pediatric sepsis definition; past, present, and future. Pediatr Crit Care Med 2005; 6 (3 Supll):S6-8.
10. Brun-Buisson C. The epidemiology of the systemic inflammatory response. Intens Care Med 2002; 26 (1 Suppl): S64-74.
11. Smith N. Sepsis: its causes and effects. J Wound Care 2003; 12 (7): 265-70.
12. Casado-Flores J, Blanco-Quiros A, Asensio J, Arranz E, Garrote JA, Nieto M. Serum procalciotonin in children with suspected sepsis: a comparison with C-reactive protein and neutrophil count. Pediatr Crit Care Med 2003; 4(2):190-195.
13. Delevaux I, Andre M, Colombier M, Albuisson E, Meylheuc F, Begue RJ, et al. Can procalcitonin measurement help in differentiating between bacterial infection and other kind of inflammatory processes? Ann Rheum Dis 2003; 62:337-340.
14. Leclerc F, Cremer R, Noiset O. Procalciotonin as a diagnostic and prognostic biomarker of sepsis in critically ill children. Pediatr Crit Care Med 2003;4:264-266.
15. Meisner M, Tschaikowsky K, Hutzler A, Schick C, Schuttler J. Postoperative plasma concentrations of procalcitonin after different types of surgery. Intensive Care Med 1998; 24:680-684.
16. Mirjam Christ-Crain, Beat Muller. Procalcitonin in bacterial infections – hype, hope, more or less? Swiss Medical Weekly 2005; 451-460.
17. Shruder J, Staubach KH, Zabel P, Stuber F, Kremer B. Procalcitonin as a marker of severity in septic shock. Langenbecks Arch Surg 1999; 384(1):33-38.
18. Cohen JB, Guyatt G, Bernard GR, Calandra T, Cook D, Elbourne D, et al. New strategies for clinical trials in patient with sepsis and septic shock. Crit Care Med 2001; 29(4):.880-886.
19. Meisner Michael. PCT, Procalcitonin – a new, innovative infection parameter. Berlin : Brahms Diagnostica, 1996.
20. Weglohner W, Struck J, Fischer-Schulz C, Morgenthaler NG, Otto A, Bohuon C, et al. Isolation and characterization of serum procalcitonin from patients with sepsis. Peptides 2001; 22 (12): 2099-103
21. Whang KT, Steinwald PM, White JC, Nylen ES, Snider RH, Simon GL, et al. Serum calcitonin precursors in sepsis and systemic inflammation. J Clin Endocrinol Metab 1998; 83: 3296–301.