International Journal of BioMedicine 3(4) (2013) 279-282

INTERNATIONAL JOURNAL OF BIOMEDICINE

BASIC RESEARCH

Encephalon Condition in Chronic Alcohol Intoxication and the Role of Amoebic Invasion of this Organ in the Development of Ethanol Attraction in Men

Sergey V. Shormanov, PhD, SD*

The Yaroslavl Medical Academy
Yaroslavl, Russian Federation

Abstract

This presentation reviews data from studies on the encephalon in 27 men ranging in age from 21 to 51 years, showing signs of chronic alcohol intoxication and who died from causes other than skull injury and 14 control subjects. The specimens were fixed in formalin or Karnua liquid, filled with paraffin and then examined, utilizing a variety of histological, histochemical and morphometric techniques. The data refers to the structural changes in the various tissue components of the brain (nervous, glia-cells, arteries, veins), as well as pertinent information concerning the presence of Protozoa in all the sections examined which according to their morphological signs and behavioral reactions indicate that amoeba had been present. The degree of cerebral tissue insemination by these parasites has been demonstrated. The condition of the membranes of these microorganisms, their cytoplasm, nucleus and nucleoli as well as the chromatoid corpuscles has been assessed and recorded. The ability of these microorganisms to split, migrate within the CNS limits, to trigger incitement and dystrophic changes and in the case of death – calcification or exulceration is shown. Further, the issue of species characteristics of amoeba occurring in the patients' brains is discussed. The hypothesis of a possible link of amebic invasion with the development of alcohol dependence in humans is proposed.

Keywords**:** *encephalon brain; chronic alcohol intoxication; amoebae role in the pathogenesis of alcoholism.*

Introduction

Indulging in alcohol consumption is sufficiently widespread in the world today and has become characteristic of all population groups, regardless of their income or social status [1,2]. The consumption of ethyl alcohol over long periods of time results in intoxication, which leads to severe pathology of the various vital systems, the encephalon being its main target [3,4]. Any type of damage to this organ, in particular, is especially significant as it changes the subject's social status and leads to the development of his or her psychological dependence on ethanol. At the same time, analysis of the literature on the subject reveals that the peculiarities of the brain microstructures of individuals frequently consuming strong alcoholic drinks has been more or less ignored or, at best, less studied. The mechanism involved in alcohol craving in certain individuals also remains unresolved [2]. Thus, the author of this publication, in one of the articles published prior [3,5], describes the phenomenon of cerebral tissue invasion by a type of microorganisms belonging to phylum Protozoa and attempts to establish a relationship between this phenomenon and the development of craving for ethanol in such individuals.

The aim of this study is to reveal the peculiarities of the structural reconstruction of various brain tissue components in subjects with chronic alcohol intoxication and establish the type of amoeba present there, and their possible role in triggering the development of dependence on ethanol in such subjects.

Material and Methods

The subject of the morphological study in this paper is the brain of two groups of men ranging in age from 21 to 51 years who died from causes other than skull injury. The autopsy was performed within 24 hours of death. The first group included 27 men showing signs of chronic alcohol intoxication. The evidence of their long-term indulgence in

***Corresponding author**: Prof. Sergey V. Shormanov. Head of Department of Pathological Anatomy. The Yaroslavl Medical Academy. Yaroslavl, Russian Federation.*
E-mail: S_V_Shormanov@rambler.ru

alcoholic drinks was confirmed based on their anamnestic findings and typical changes observed in their internal organs [1,4]. The cause of death of these individuals was alcoholic delirium or post hemorrhagic anemia related to the injury of the major blood vessels and the heart. The second group was the control group, which included 14 men who died violent deaths, chiefly caused by knife wounds, resulting in copious bleeding. The state of the internal organs and the anamnestic data allowed exclusion of the indulgence of those individuals in imbibing alcoholic drinks. Both the right and the left hemispheres were examined microscopically with particular attention being paid to the cortex of the frontal and the posterior central flexures, as well as the cortex of the inferior frontal, superior temporal and superior occipital flexures. Besides the medial nucleus of the optic thalamus, the mammillary corpuscles, the hippocampus, the corpus callosum, the cortex and the cerebellar-dentate nucleus and myelencephalon were studied in detail. The encephalon specimens were fixed in 10% neutral formalin or Karnua liquid and paraffin was poured. Histological sections were stained using hematoxylin and eosin, according to Nissle, Masson and Hart. In addition, a carbohydrate histochemical reaction was performed in line with the work of McManus. Morphometry was conducted using a screw ocular-micrometer.

Results

On microscopic examination of the material the brain vessels were revealed as being filled with blood. Both the arteries and veins of this organ revealed signs of sclerosis and hyalinosis (Fig.1a), and throughout the length of their circulatory flow, infiltrates composed of mononuclear cells were observed. Sometimes, hemorrhagic spots containing hemosiderin were found in the brains of the dead individuals (Fig. 1b).

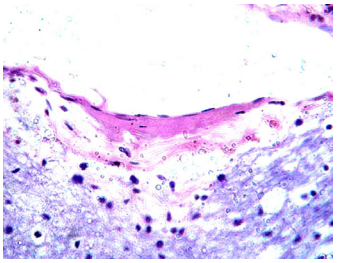

Fig. 1 a.
Hyalinosis of the cerebral artery wall. Stained with Hematoxylin & Eosin x 100.

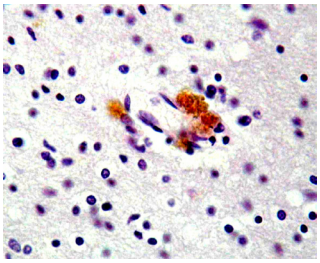

Fig. 1b.
Hemosiderin blocks in the site of old haemorrhage. Stained with Hematoxylin & Eosin x 200.

The nerve cells were heterogeneous in structure, of which some appeared to be normal cells, whereas others were in the state of acute swelling up, with vacuole dystrophy (Fig. 1c) or containing a grain of lipofuscin in their cytoplasm. In every experiment, in different parts of the brain, neurocytes showing signs of atrophy were revealed. These were somewhat reduced in size, having intensively-colored cytoplasm due to the background dye; however, detached tigroid grains were lacking. An important element observed in the structural reconstruction of the brain in these patients was the presence of either focal or diffuse glial cell proliferation. The latter was accompanied by impoverishment of the cortex and its neurocyte nuclei. From the various sections taken from some of the dead individuals with the signs of chronic alcohol intoxication, small-sized cysts, foci of demyelization and even calcium deposits in intricate shapes of conglomerates were detected (Fig. 1d).

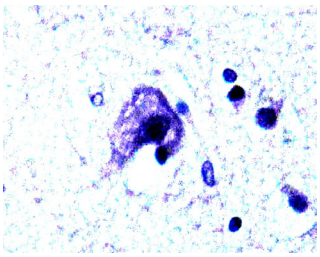

Fig. 1c.
Vacuole dystrophy of the nerve cell. Stained with Hematoxylin & Eosin x 400.

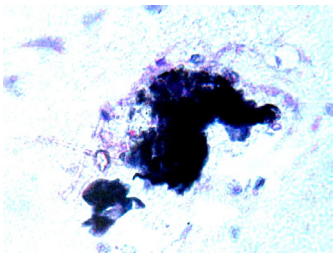

Fig. 1d.
A focus of lime sedimentation. Stained with Hematoxylin & Eosin x 200.

Besides the findings (described above) in the cerebral tissue of 65% of subjects belonging to the first group in this study, the presence of large microorganisms was observed, which, judging by their morphological signs, corresponded to phylum Protozoa. The frequency of their detection depended upon the nature of the brain section under study. For instance, in the cortex they occurred in 94% of cases, in the cerebellum – in 78%, in the myelencephalon – 58%, and finally in the optical thalamus – 47%. However, in the remaining sections of the brain they could be detected only in 3% of each. In most cases, the parasites were localized in several areas of this organ. The degree of their insemination of the cerebral tissue varied from case to case, at times in the corresponding area of the brain only a single parasite was found, whereas in others, they occurred in groups of 3-15 and more species were identified (Fig. 2a). They were identified in the control group as well, but they were the rarest findings and were represented by single microorganisms.

The parasites were between 6 to 50 microns in size and their shape, in most cases, was round or oval (Fig. 2a), having either even or scallop-shaped contours (Fig. 2b).

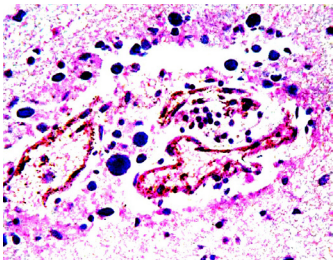

Fig. 2a.
Accumulation of oval- and round-shaped parasites along the cerebral vessels. Stained with Hematoxylin & Eosin x 100.

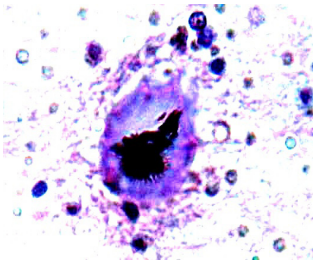

Fig. 2 b.
The scalloped shape of the parasite. The presence of chromosome-like bodies in cytoplasm. Stained with Hematoxylin & Eosin x 400.

In several cases, long outgrowths were seen spreading from the bodies of the microorganisms described which disappeared in the brain tissue (Fig. 2c). The nucleus most often was found in the center, eccentrically or just below the membrane, as if pushing it externally. It had a round or ellipsoid form containing nucleoli as small as 2-5 microns in

the middle. Sometimes, the nucleus was absent in the section, although sections with two or more nuclei were also present! The cytoplasm was stained blue with hematoxylin and eosin, purple – according to Masson, light-blue – according to Nissle and grey – according to Hart. According to McManus, the parasites became crimson in color indicating their high glycoprotein content. The peripheral regions of their bodies appeared transparent and homogeneous, whereas those in the middle had a muddied appearance and were good. Quite frequently, various inclusions were observed within the cytoplasm of the Protozoa discovered. In some cases basophilic cells were noted, round, ellipsoid or irregular in shape, whereas in the others, they resembled dark-blue needle-like crystals, which were located either in the cytoplasm or scattered or even piled one upon another forming fancy shapes (Fig. 2b,e) in various sizes, and in a few others, even vacuoles or large granular structures were found. Most of them had a regular cellular membrane on the outside, but encapsulated objects were also recorded. The capsule had a two-layered shell about 1-2 microns (Fig. 2d) in thickness. Sometimes, a septum or several septa (Fig. 2d) dividing the body into parts were seen branching from this membrane into the parasite's body. In this particular case, several parasites were found in one single capsule.

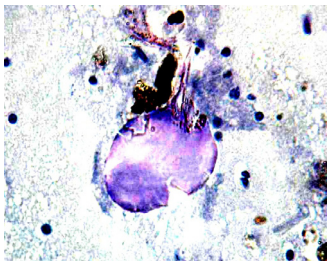

Fig. 2c.
Long outgrowths coming from the parasite inside the cerebral tissue. Granular decay of the surrounding cerebral tissue. Macrophagal infiltration. Stained with Hematoxylin & Eosin x 160.

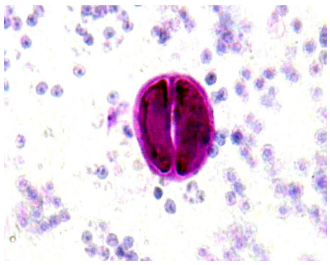

Fig. 2d.
The capsule surrounding the parasite and the formed septum. Stained according to McManus x 400.

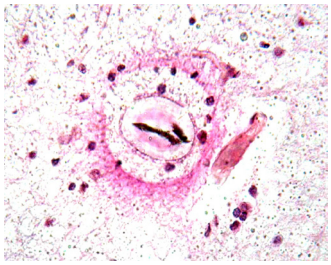

Fig. 2e.
Chromosome-like bodies in parasite's cytoplasm. The swelling of the surrounding cerebral tissue. Macrophagal infiltration. Stained according to McManus x 100.

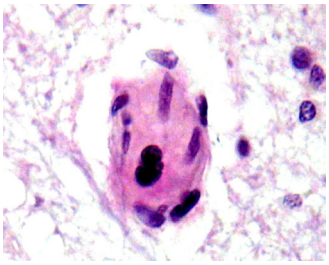

Fig. 2f.
A parasite in the vessel lumen. Stained according to McManus x 400.

On assessment of their structural peculiarities, Protozoa discovered were revealed to be amebae. This was proven by the size, shape and localization of the nucleus or nuclei. The scalloped shape and long sprouts, arising from some parasites, were connected to the pseudopodia on their surface, a characteristic sign of amoeba [5,6]. The connection with the latter is also proven as the bodies of the microorganisms bodies are divided into two zones: the glassy peripheral region called periplast and granular central region, referred to as the endoplasm [7]. Some researchers attribute the phenomenon to the ability of the cytoplasmic colloids within the amebae to change their physical state from periplastic gel to endoplasmic sol according to their surrounding environment [8]. Their reference to the amoeba is also proven by the characteristic basophilic cytoplasmic inclusions of various kinds, called chromosome-like bodies [9]. Many researchers have recorded their origin as indistinct, although several other authors consider them to be crystalline ribosomal aggregations [8]. Some of these organelles are enclosed by a double layered covering, which is typical of encysted amoeba.

In several cases, we could actually watch the signs of reproduction of the parasites, most often by gemmation. But sometimes, the nuclear membrane became indistinct and the diaster formation of the chromosomes was visible, revealing the cell's entry into the mitotic cycle. Once completed, the ameba divided into two daughter individuals. The slides show them initially located side by side, but completely separate, each with its own nuclei and often chromosome-like bodies.

In several cases, the brain did not react to amebic invasion; in others a granular decay of the bordering cerebral tissue or even a zone of abrupt swelling, surrounded by macrophage cells was observed (Fig. 2c,e). In some cases, the parasites were surrounded by small groups of leukocytes.

It should be noted that the amoeba were found in the brain of individuals with chronic alcohol intoxication, not only in the neural tissue proper, in some cases, they were located in the lumen of the cerebral arteries and veins (Fig, 2f), as well as between the cerebral shells. This could prove their migration, either actively (with the help of pseudopodia or passively (floating in blood or liquor)).

Some amoeba ended their lifecycle and simply died. Morphologically, their bodies were saturated with fluid containing some vacuoles in their cytoplasm, or vice versa, when dehydration and wrinkling of the parasites took place. Later, these microorganisms underwent fragmentation and were lyzed. Infrequently, the bodies of the dying amoeba were encrusted with lime and they could remain in the brain in that state for an indefinitely long period of time.

Discussion

Therefore, prolonged addiction to alcohol is accompanied by gross organic changes in various tissue structures of the human brain. First, the cerebral vessels are damaged, resulting in their sclerosis and hyalinosis. The appearance of the perivascular infiltrates from the mononuclear cells can be linked along with the immune reaction to the damage of the arterial and venous walls on repeated exposure to ethanol. New cerebral hemorrhages are due to delirium alcoholicum, while the older ones are the result of earlier occasions of acute alcoholization [2,4]. Ethanol also affects the nerve cells, causing dystrophic and atrophic changes and their ultimate death. Focal and diffuse glial cell proliferation is considered an important morphological manifestation of alcohol-induced brain damage [10]. The white matter of the brain is also

affected, showing various foci of demyelination in its regions. The cases of petrification and microcysts evident are logical results of calcification or resorption of the necrotic foci of the cerebral tissue, formed during repeated episodes of the patient's alcoholization.

Against the background of the cerebral changes connected with alcoholic encephalopathy, described thus far, the amoeba have been identified in various regions of the brain, in most patients in the study. Identification of the species was very important. There are tens of species of these parasites occurring in nature [8], but only the amoeba belonging to the limax group viz., Naegleria and Acanthamoeba, living in soil and stagnant water, can directly penetrate into the human brain. Their significance in human pathology became better recognized after being recorded in many countries as a disease accompanied by severe cerebral damage, and named primary amebic encephalitis [11]. The immediate anamnesis of most of the patients indicated they had bathed in lakes and ponds prior. In the cerebrospinal fluid of some patients, the presence of amoeba like Naegleria and Acanthamoeba was revealed. They had penetrated into the nasal cavity along with contaminated water and then entered into the cranial cavity and the brain through the olfactory plate [8]. They are difficult to distinguish but judging from their morphological signs and behavioral reactions one can arrive at a correct diagnosis.

The Naegleria amoeba always causes an acute brain fever, which is by itself highly lethal [12]. The disease is characterized by first involving the brain membranes, and next developing surface encephalitis. Numerous parasites are revealed in the cortex. As opposed to the parasites in this study, they are smaller in size and do not form cysts in the tissues [8].

The Acanthamoeba, apart from acute condition, can cause a slow-moving clinically negative chronic inflammatory process [6,13], simultaneously affecting the membranes and various other regions of the brain and cerebellum. Similar to the parasites in the present study, they grow considerably big, are characterized by the division of protoplasm into two zones, contain chromosome-like bodies and are able to become encysted in the tissues. Besides, they can exist in the human body as saprophytes, as they have been identified in the nasopharyngeal washout of healthy individuals [6,14].

The facts described allow us to conclude that the parasites in the present study are most likely closer to the latter type of amebae, the Acanthamoeba. From the data collected in this study, no morphological signs of meningoencephalitis in the brain and cerebral membranes were observed, nor had the patients revealed any clinical manifestations of the disease while alive. Thus, the amoeba revealed in this study behave like messmates, although they sometimes cause local reactive changes in the cerebral tissue. Nevertheless, one should note a much higher concentration of their presence in the brain of alcohol-addicted individuals, more than in the brain of those of the control group. It is known that ethanol weakens the activity of the T- and B-lymphocytes and depresses the immune system [15]. Evidently, on regular consumption of alcohol and during episodes of alcoholization becoming more and more prolonged and frequent, the saprophytic microflora, including amoeba, located in the mucous lining of the nasal cavity, becomes active. These amoeba penetrate the cranial cavity and spread within the brain. It is highly essential to identify this phenomenon in the progression of alcoholic pathology. Being parasitic in the cerebral tissue, the amoeba might augment, through certain mechanisms, the development of a physical and psychological addiction to ethanol, i.e. the transition from chronic intoxication to alcoholism. An analogy can be drawn to *Helicobacter pylori*, which for decades has been considered a gastric saprophyte and proven to be linked with the appearance and progression of chronic gastritis and ulcers. The hypothesis can be significantly perspective in the treatment of alcoholism. It is indirectly proven by clinical practice. Some medicines with an anti-alcoholic effect, e.g. Klion (metronidazole) possess a pronounced anti-amebic effect. It is quite logical to suppose the latter fact being connected with their ability to penetrate through the hematoencephalic barrier and to suppress the activity of amoeba in the brain, thus reducing the patients' inclination for ethanol.

References

1. Kaktyrskiĭ LV. Clinical morphology of alcoholic cardiomyopathy. Arkh Patol 2009; 71(5):21-3. [Article in Russian].
2. Paukov VS, Beliaeva NYu, Voronina TM. Alcoholism and alcohol disease. Ter Arkh 2001; 73(2):65-7. [Article in Russian].
3. Shormanov SV . Protozoan infection of the human brain. Fund Issl 2004; 1:118-9. [Article in Russian].
4. Shormanov SV. Structural alterations of the brain in patients with chronic alcoholism. Arkh Patol 2006; 68(1):19-22. [Article in Russian].
5. Shormanov SV . The protozoan-infected brain in alcohol abusers. Med Parazitol 2010; 1:22-27. [Article in Russian].
6. Daiter AB, Tumka AF. Parasitic diseases. Leningrad: Medicine; 1980. [Book in Russian].
7. Oliva S, Jantz M, Tiernan R, Cook DL, Judson MA. Successful treatment of widely disseminated acanthamoebiasis. South Med J 1999; 92(1):55-7.
8. Knight R. Parasitic Disease in Man. Edinburg, London, Melbourne and New York, Longman Group Limited;1992.
9. Demin SIu, Skarlato SO, Prodeus TV. Chromosome-like bodies of dysentery amoeba Entamoeba histolytica. Tsitologiia 2001; 43(11): 1080-7. [Article in Russian].
10. Damulin IW . Alcoholic degeneration of cerebellum. Ross Med Zh 2005; 2:44-7. [Article in Russian].
11. Butt CG. Primary amoebic meningoencephalitis. New Engl J 1966; 274(26):1473-6.
12. Barnett ND, Kaplan AM, Hopkin RJ Saubolle MA, Rudinsky MF. Primary amoebic meningoencephalitis with Naegleria fowleri: clinical review. Pediatr Neurol 1996; 15 (3):230-4.
13. Cleland PO, Lawande RV, Onyemelukwe G, Whittle HC. Chronic amoebic meningoencephalitis. Arch Neurol 1982; 39(1): 56-57.
14. Wang SS, Feldman HA. Isolation of Hartmannella species from human throats. New Engl J Med 1967; 277 (22): 1174-9.
15. Zabrodskii PF, Kirichuk VF, Osipov OV. In vitro effects of alcohols and their metabolites on antibody-forming activity of T and B lymphocytes. Bull Exp Biol Med 2002; 133(3):258-60. [Article in Russian].