International Journal of Biomedicine 9(2) (2019) 128-130
http://dx.doi.org/10.21103/Article9(2)_OA9

ORIGINAL ARTICLE

General Surgery

INTERNATIONAL JOURNAL OF BIOMEDICINE

The Results of Applying the Original Colostomy in Patients with Acute Large Bowel Obstruction

Alexei L. Charyshkin, PhD, ScD*; Erik A. Keshyan; Oleg V. Midlenko, PhD, ScD; Antonina V. Smolkina, PhD, ScD; Nikolai I. Belonogov, PhD, ScD

Institute of Medicine, Ecology and Physical Education of Ulyanovsk State University
Ulyanovsk, the Russian Federation

Abstract

The results of the original method of colostomy formation in 67 patients with acute large bowel obstruction (ALBO) were studied. All patients underwent sigmoid colon resection with the colostomy formation. In total, postoperative complications of a purulent-inflammatory nature (skin maceration, suppuration of postoperative and paracolostomic wounds, necrosis of colostomy, abscess of the abdominal cavity, and paracolostomal fistula) in both groups were observed in 30 (44.8%) patients. In Group 1 (n=40), with the classical method of colostomy formation, purulent-inflammatory complications were observed in 21 (52.5%) patients, in Group 2 (n=27) with the original method of colostomy formation in 4 (14.8%) patients. Bleeding from colostomy and colostomy prolapse occurred only in Group 1 in 8 (20%) patients. The proposed method of applying a colostomy helps reduce purulent-inflammatory complications by more than 3 times and provides prevention of bleeding and colostomy prolapse. (**International Journal of Biomedicine. 2019;9(2):128-130.**)

Key Words: colon cancer • acute large bowel obstruction • colostomy • postoperative complications

Introduction

In patients with acute large bowel obstruction (ALBO), the main cause of the disease is neoplasm of the left colon and rectum.[1-4] The leading method of treatment for ALBO is emergency surgery [5-7] with the formation of a temporary or permanent colostomy.[1-4,8]

The presence of colostomy in patients reduces the quality of life; often there are specific complications: maceration of the skin, suppuration of the postoperative and paracolostomal wounds, necrosis of the colostomy, abscess of the abdominal cavity, paracolostomal fistula, colostomy prolapse, and parastomal hernia.[3,4,7] Improving the colostomy formation and methods for drainage of the paracolostomal space is an urgent task in surgery of the large intestine.

The aim of our study was to improve the method of colostomy formation in patients with ALBO.

***Corresponding author**: *Prof. Alexei L. Charyshkin, PhD, ScD, Head of the Faculty Surgery Department, Institute of Medicine, Ecology and Physical Education, Ulyanovsk State University. Ulyanovsk, the Russian Federation. E-mail: charyshkin@yandex.ru*

Materials and Methods

We analyzed surgical outcomes in 67 patients (aged 50 to 70 years, mean age of 55.2) with ALBO, who underwent surgical treatment in Ulyanovsk City Clinical Emergency Hospital and O.M. Filatov City Clinical Hospital №15 (Moscow) in the period from 2010 to 2019.

The study was conducted in accordance with ethical principles of the Declaration of Helsinki and approved by the by Ethics Committees at our institutions. All patients underwent sigmoid colon resection with the colostomy formation. Patients were divided into two groups depending on the method of colostomy formation. In Group 1 (n=40), we performed the classical colostomy; in Group 2 (n=27), a colostomy was performed according to the developed technique (Fig.1): "A method for the prevention and treatment of inflammatory complications of colostomy" (Application for invention No. 2014122739; Priority of 06/21/2018) (Authors: A.L. Charyshkin and E.A. Keshyan).

Technique of the original method of colonostomy formation

In the anterior abdominal wall in the direction of the intended projection of the stoma, we form a hole; then we

place interrupted sutures between skin, aponeurosis and parietal peritoneum, and the colostomy is fixed with these uncut ligatures. The peculiarity is that before the interrupted sutures are applied around the hole for the stoma and away from the hole edge by 3-4 cm, the first catheter is installed through holes throughout the way into the preperitoneal space of the paracolostomal zone. This is done by fixing catheter to the parietal peritoneum with two interrupted sutures from absorbable material. The distal end of the catheter is displayed on the anterior abdominal wall through a separate hole (contour section) in the skin, departing 2.0 cm from the lower edge of the skin wound. The second catheter is installed through holes in the subaponeurotic space around the hole for the stoma, away from the hole edge by 3-4 cm, by fixing two interrupted sutures from absorbable material to the aponeurosis. The distal end of the catheter is displayed on the anterior abdominal wall through a separate hole (contra-aperture) on the skin, departing 2.0 cm from the upper edge of the skin wound. In the postoperative period, local anesthetic for anesthesia and an antibacterial drug for the prevention and treatment of purulent-inflammatory complications are alternately administered through catheters.

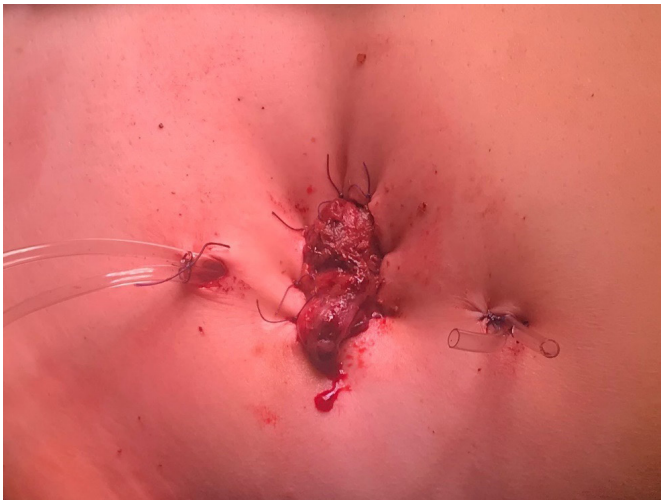

Fig. 1. *The final appearance of the original colostomy.*

All patients underwent general clinical and laboratory, radiographic, endoscopic, ultrasound, and histological methods of investigation; whenever required, echocardiographic study was carried out. Leukocyte index of intoxication (LII) was calculated by the formula of V.K. Ostrovsky.[9]

Statistical analysis was performed using the statistical software «Statistica» (v6.0, StatSoft, USA). All values are presented as mean±SEM). The inter-group comparisons were performed using Student's t-test. A probability value of $P<0.05$ was considered statistically significant.

Results and Discussion

Analysis of the data showed that in the early postoperative period pain disappeared within 5.1±0.2 days and 8.3±0.4 days after surgery in Group 2 and Group 1, respectively, Group 2 being significantly shorter by 3 days.

Comparison of data on the timing of intestinal motility recovery in the early postoperative period (Table 1) showed that in Group 1 paresis was resolved within 6.2±0.3 days, the active functioning of the colostomy occurred within 5.7±0.3 days, and in Group 2 - 2.8±0.2 days and 2.7±0.2 days, respectively ($P<0.05$).

Table 1.
The timing of intestinal motility recovery

Duration of clinical symptoms (day)	Group 1	*P*-value	Group 2
Paresis	6.2±0.3	0.000	2.8±0.2
Active functioning of thecolostomy	5.7±0.3	0.000	2.7±0.2

On the eighth day after the operation, the LII decreased to the standard value in Group 2 and exceeded the standard values by 2 times in Group 1 (Table 2).

Table 2.
Dynamics of LII in the postoperative period

Group	LII index after the operation			
	Day 4	Day 6	Day 8	Day 10
Group 1	8.7±0.3	4.8±0.3	4.3±0.3	2.5±0.2
P-value	>0.05	0.000	0.000	0.007
Group 2	8.4±0.4	3.1±0.2	1.4±0.2	1.5±0.3

In total, postoperative complications of a purulent-inflammatory nature (skin maceration, suppuration of postoperative and paracolostomic wounds, necrosis of colostomy, abscess of the abdominal cavity, and paracolostomal fistula) in both groups were observed in 30 (44.8%) patients. In Group 1, with the classical method of colostomy formation, purulent-inflammatory complications were observed in 21 (52.5%) patients, in Group 2 with the original method of colostomy formation in 4 (14.8%) patients. Bleeding from colostomy and colostomy prolapse occurred only in Group 1 in 8 (20%) patients.

Reducing the incidence of postoperative inflammatory complications by more than 3 times, eliminating complications such as bleeding from the colostomy and colostomy prolapse in Group 2 is associated with the original method of draining the preperitoneal and subaponeurotic spaces of paracolostomal zone and introducing local anesthetics and antibacterial drugs through catheters in the postoperative period.

Findings

1. Active functioning of the original colostomy occurs 72 hours earlier than with the traditional colostomy.

2. The proposed method of applying a colostomy helps reduce purulent-inflammatory complications by more than 3 times and provides prevention of bleeding and colostomy prolapse.

Competing Interests

The authors declare that they have no competing interests.

References

1. Gataullin IG, Savinkov VG, Frolov SA, Kozlov AM. [Predictor of septic complications in colorectal cancer surgery]. Journal of Experimental and Clinical Surgery. 2018;11(1):33-37. doi: 10.18499/2070-478X-2018-11-1-33-37. [Article in Russian].
2. The state of cancer care for the population of Russia in 2016. In: Kaprina AD, Starinsky VV, Petrova GV, editors. M.: MNIOI named after PA. Herzen; 2017. [In Russian].
3. Tsarkov PV, Tulina IA, Tsugulya PB, Kochetkov VS, Khmelik SV. [Post-rectectomy choice of preventive intestinal stoma formation method: prospective multicenter randomized clinical trial protocol]. Russian Journal of Gastroenterology, Hepatology, Coloproctology. 2017;27(2):102-110. doi:10.22416/1382-4376-2017-27-2-102-110. [Article in Russian].
4. Charyshkin AL, Aberyasev SYu, Mokhovikov VA. [Formation of reservoir colostomy]. Kazan Medical Journal. 2010;91(2):215-8. [Article in Russian].
5. Geng HZ, Nasier D, Liu B, Gao H, Xu YK. Meta-analysis of elective surgical complications related to defunctioning loop ileostomy compared with loop colostomy after low anterior resection for rectal carcinoma. Ann R Coll Surg Engl. 2015 Oct;97(7):494-501. doi: 10.1308/003588415X14181254789240.
6. Glynne-Jones R, Wyrwicz L, Tiret E, Brown G, Rödel C, Cervantes A, Arnold D; ESMO Guidelines Committee. Rectal cancer: ESMO Clinical Practice Guidelines for diagnosis, treatment and follow-up. Ann Oncol. 2017;28(suppl_4):iv22-iv40. doi: 10.1093/annonc/mdx224.
7. Japanese Society for Cancer of the Colon and Rectum (JSCCR) guidelines 2016 for the treatment of colorectal cancer. Watanabe T, Muro K, Ajioka Y, Hashiguchi Y, Ito Y, Saito Y, et al.; Japanese Society for Cancer of the Colon and Rectum. Int J Clin Oncol. 2018;23(1):1-34. doi: 10.1007/s10147-017-1101-6.
8. Yanishev AA, Bazaev AV, Kokobelyan AR, Abelevich AI. [Current technologies for the prevention of parastomal herniation (review)]. Sovremennye Tehnologii v Medicine 2018;10(3):175–183. doi: 10.17691/stm2018.10.3.22. [Article in Russian].
9. Ostrovskiĭ VK, Alimov RR, Mashchenko AV, Semenova OP, Kurapova MI. [Normal parameters of leukocytic index of intoxication]. Klin Lab Diagn. 2003;(1):45-6. [Article in Russian].